

Courtesy of Todd H. Nalley, DDS, MS

LANAP® Periodontist since 2011, Carlsbad, CA

PATIENT HISTORY

A 70 year-old male in good overall health was referred for pre-prosthetic ridge augmentation in the maxillary anterior segment. A full periodontal exam revealed a large periodontal defect on the distal aspect of tooth #29, which was also the anterior abutment of a fixed bridge. The patient was asymptomatic in the lower right quadrant.

TREATMENT APPROACH

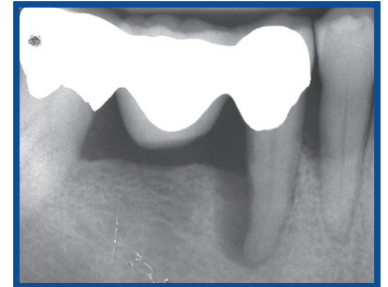
Treatment was provided as request in the maxillary arch, but during the healing phase, laser periodontal therapy (LANAP) was performed for the lower right quadrant.

Tooth #29 had a reduced response to pulp testing, therefore a combined perio-endo lesion was a possibility. Treatment was performed without any complication. Occlusal adjustment was made for both #29 and pontic #30 to a significant degree.

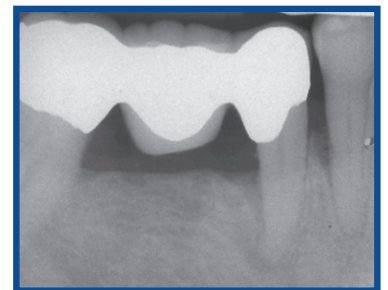
RESULTS

At subsequent post-op visits, there were no pulpal symptoms for tooth #29. X-rays were taken at an earlier interval due to concern over periapical lesion.

The patient continued periodontal recall visits with no complaints or symptoms in the lower right quadrant. His home care improved dramatically due to his encouragement over the possibility of saving his fixed bridge. At 6 months and then 15 months, the radiographic improvements were significant and the probing depths were within normal limits.



Pre-Op



15 Months Post-Op



ABOUT THE AUTHOR: TODD H. NALLEY, DDS, MS

Dr. Nalley received his dental degree from the University of the Pacific, San Francisco and proceeded onto graduate school at the University of Iowa where he earned a Master of Science degree and Certificate in Periodontics in 1978. In addition, he served as periodontal resident at the VA hospital in Iowa City, Iowa. He trained in the LANAP® protocol for treatment of periodontally involved teeth and implants in 2011. He is a member of the American Academy of Periodontology; the American Dental Association; the California Society of Periodontists and serves as Region Director; and the San Diego County Periodontists and serves as Executive Director. He maintains a private practice limited to Periodontics in Carlsbad, California.

DR. NALLEY
VIDEO TESTIMONIAL

SCAN
QR CODE

