

Case 1: Mr. MF

A 73 year-old Caucasian male presented to our office; his chief complaint was discomfort. An x-ray showed vertical bone loss on M implant #18.

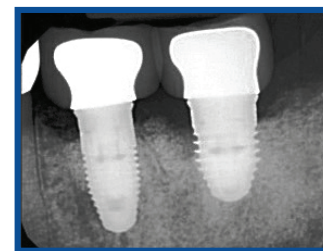
Patient accepted the LAPIP protocol using the PerioLase MVP-7 Nd:YAG laser, with 430 Jules total delivered. Occlusal adjustment was performed the day of treatment, and post-operative visits at two weeks, two months and six months. X-rays were taken at the six month post-operative visit and periodontal probing was completed.

Case 2: Ms. JE

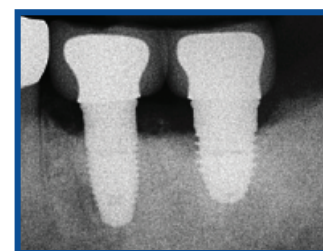Ms. JE is a 75 year-old Caucasian female who presented to our office, again the primary complaint was discomfort. Radiographs indicated vertical bone loss on D tooth #14.

Treatment with the PerioLase MVP-7 Nd:YAG laser isolated to teeth 13,14, and 15 with 1167 Jules total delivered. Occlusal adjustments were performed on the day of treatment, and visits two weeks post-op, two months post-op, and six months post-op. Clinical exam at 6 months included radiographs and periodontal probing.

Case 1: Mr. MF

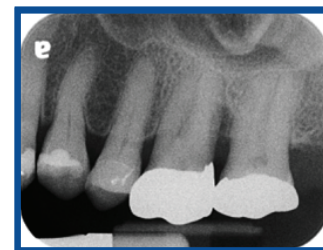

Pre-Op
#18: 6,5,10 | 10,6,6
#19: 5,5,10 | 10,7,5

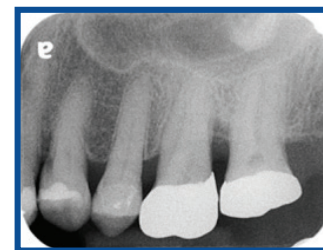

6 Months Post-Op
#18: 4,5,5 | 5,4,4
#19: 5,5,5 | 5,4,4

Case 2: Ms. JE



Pre-Op
#14: 3,5,9 | 8,4,3



6 Months Post-Op
#14: 3,3,5 | 5,3,3



**ABOUT THE AUTHOR:
POORIA FALLAH, DDS**

Dr. Fallah completed his periodontal training at New York University where he received awards for clinical, scholarly and professional excellence. In addition, Dr. Fallah completed the Implantology Preceptorship Program at the University of California Los Angeles (UCLA). Dr. Fallah currently practices in Dallas, TX and lectures nationally and internationally.

SEE MORE
LAPIP RESULTS

SCAN
QR CODE