

Courtesy of Alice Urbankova, DDS, PhD

LANAP General Dentist since 2017

Private Practice, PreserveYourTeeth Dentistry[®] at
Rockefeller Center, New York City and East Setauket, New York

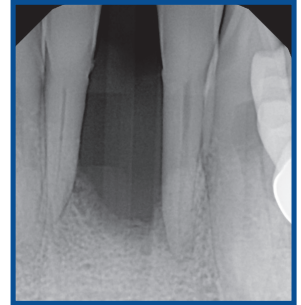
PATIENT HISTORY

A 56 year-old female presented to our office on April 17, 2017 for an emergency visit. She was holding her lower front tooth #24 in her hand. Previously, other dentists had told her that many of her teeth were hopeless and needed to be extracted. Replacing her missing tooth was her primary concern.

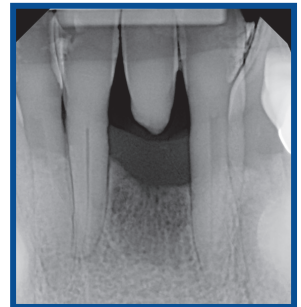
Clinical examination revealed generalized deep pockets with attachment loss, generalized bleeding on probing, gingival edema, heavy calculus and biofilm, and multiple sites with suppuration. Teeth #2, 3, 14, 15, 17, 18, 19, 20, 21, 28, 29, 30, and 31 all had class 3 mobility.

Several teeth were depressible and an unpleasantly strong mouth odor permeated the room, which was noticeable to all and embarrassing to the patient. Probing depths ranged from 6 to 12 mm. Radiographs revealed generalized advanced bone loss, with localized angular defects and evidence of calculus. She was diagnosed with generalized advanced aggressive periodontitis. The overall prognosis was poor.

The patient received an explanation of the diagnosis and treatment options were offered, including full mouth LANAP surgery. Alternative treatment included traditional periodontal therapy (scaling and root planing, osseous surgery, and multiple tooth extractions). The patient was informed that many of her teeth were considered hopeless, but that if she were unwilling to undergo extractions, she could still be treated as a part of the protocol. The patient was further warned that the teeth may not respond to the therapy and may later need to be extracted.



Pre-Op: April 2017
#23: 7,4,5 mm | 6,4,8 mm
#25: 6,4,6 mm | 7,4,9 mm



Post-Op: June 2018
#23: 2,2,3 mm | 4,3,5 mm
#25: 3,2,3 mm | 7,3,4 mm

	①	②	③	④	⑤	⑥	⑦	⑧	⑨	⑩	⑪	⑫	⑬	⑭	⑮	⑯
MAXILLARY																
	DCM	DCM	DCM	DCM	DCM	DCM	DCM	DCM	MCD	MCD	MCD	MCD	MCD	MCD	MCD	MCD
Facial 4/25/2017	8 6 8	9 9 8	8 4 8	8 4 8	7 4 5	4 4 4	4 2 4	6 2 5	5 2 6	8 4 9	9 4 9	8 4 8	8 5 9	9 4 6	---	0
Change		▲▲▼	▲▼▲	▲▲	▲▲		▼▲	▲▲	▲▲	▲▲	▲▲	▲▲	▲▲	▲▲	▼	
6/19/2018	8 6 8	7 6 9	8 5 5	5 4 6	6 4 5	4 4 4	4 3 3	3 2 3	3 2 3	3 2 7	7 2 6	7 2 8	6 2 6	9 4 8	---	0
Lingual 4/25/2017	9 6 7	8 4 5	9 6 6	7 4 7	7 5 6	6 4 6	5 4 4	5 4 6	6 4 6	6 4 6	7 4 7	7 4 7	7 4 8	8 4 4	---	0
Change		▲▼	▲▲	▲▲	▲▲	▲▲	▲▲	▲▲	▲▲	▲▲	▲▲	▲▲	▲▲	▲▲		0
6/19/2018	9 6 7	7 4 6	8 4 5	5 2 5	5 2 3	3 1 2	2 1 2	2 3 4	4 3 4	4 3 4	4 3 4	4 3 4	5 4 6	6 4 4	---	0
MANDIBULAR																
	DCM	DCM	DCM	DCM	DCM	DCM	DCM	DCM	MCD	MCD	MCD	MCD	MCD	MCD	MCD	MCD
	⑳	㉑	㉒	㉓	㉔	㉕	㉖	㉗	㉘	㉙	㉚	㉛	㉜	㉝	㉞	㉟
Lingual 4/25/2017	8 6 6	7 6 7	7 6 8	8 4 8	8 4 7	7 4 6	7 4 6	6 4 6	0 0 0	7 4 5	5 4 6	6 4 8	8 4 7	6 4 6	7 5 9	6 6 6
Change	▲▼	▲▲	▲▼	▲▼	▲▼	▲▲	▲▲	▲▲		▲▲	▲▲	▲▲	▲▲	▲▲	▲▲	▲▲
6/19/2018	6 6 7	4 6 6	4 6 6	4 6 6	6 6 4	6 2 3	3 2 3	3 2 3	0 0 0	2 2 3	3 2 3	4 3 4	5 4 6	6 4 5	4 4 6	5 3 4
Facial 4/25/2017	9 6 7	9 5 8	8 4 8	8 4 8	8 4 9	8 4 7	8 4 7	7 4 9	0 0 0	6 4 8	7 8 8	8 4 9	9 4 9	9 5 9	9 6 9	6 6 6
Change	▲▲	▲▲	▲▲	▲▲	▲▲	▲▲	▲▲	▲▲		▲▲	▲▲	▲▲	▲▲	▲▲	▲▲	▲▲
6/19/2018	6 4 7	7 4 7	6 4 5	4 3 4	6 4 7	7 4 6	6 4 5	7 3 4	0 0 0	4 3 5	5 4 5	4 3 4	4 3 6	5 4 6	4 3 9	4 3 4

Courtesy of Alice Urbankova, DDS, PhD

LANAP General Dentist since 2017

Private Practice, PreserveYourTeeth Dentistry[®] at

Rockefeller Center, New York City and East Setauket, New York

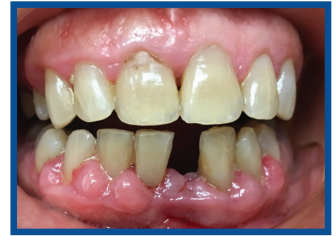TREATMENT APPROACH

The patient chose to accept the LANAP protocol and forego tooth extraction for the time being. LANAP treatment was performed in two visits one week apart as per the protocol, which included occlusal adjustment, anterior periodontal splint with #24 pontic tooth, occlusal appliance and routine maintenance visits.

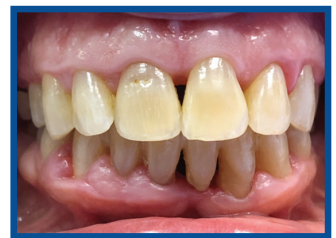RESULTS

The patient was compliant and presented as per protocol at the 1, 3, 6 and 9-month visits. During those visits, we observed decreased gingival redness, absence of suppuration, decreased mobility and radiographic evidence of new bone. At the 12-month visit, signs of inflammation were minimal, except for the posterior teeth that had been considered hopeless where bleeding on probing was still present. No mouth odor was present. Teeth #2, 3, 17, and 18 had class 1 mobility, and the remaining teeth showed no mobility and none of the teeth were depressible. At multiple sites, we observed horizontal bone growth radiographically.

The patient was very comfortable and happy with the results, and stated that she "felt better than [she had] in many years." After the one year LANAP follow up, the patient has decided to do a second round of "touch up" laser treatment aimed at the posterior teeth that had been initially considered hopeless, that were now less mobile and no longer depressible. Hence, 15 months after the patient presented with 13 hopeless teeth, she had lost none and was interested in further laser treatment in order to further control her disease.



Pre-Op: April 2017



Post-Op: June 2018



ABOUT THE AUTHOR: ALICE URBANKOVA, DDS, PHD

Alice Urbankova DDS, PhD obtained her doctorate of dental surgery from Columbia University College of Dental Medicine and is a graduate of Palacky University where she received the doctorate of medicine and her PhD. She served as full time faculty at Columbia University and was Director of the Division of Operative Dentistry at Stony Brook University School of Dental Medicine, and adjunct Clinical Assistant Professor at New York University College of Dentistry. She is the owner of PreserveYourTeeth dentistry with locations in East Setauket, NY and Rockefeller Center in Manhattan. Her practice focuses on prevention of oral diseases, general dentistry, periodontics and regenerative dentistry with the goal of preserving teeth and improving oral health.

