

PATIENT HISTORY

A 52 year-old female, in good overall health, was referred for evaluation of what appeared to be a failing implant in the #19 position. The fixture was approximately two years old and the restorative dentist had noted the problem during routine dental recall. The patient was referred back to the surgeon who had placed the implant, but no recommendations for treatment were made. The patient was then referred to our office as a second opinion.

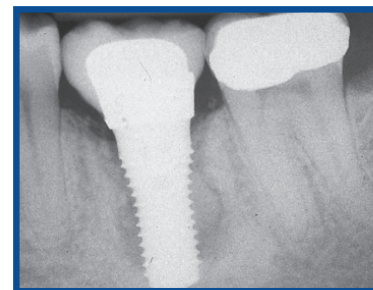
#19 area presented with acute inflammation, exudate around the fixture, and 8-12mm pocketing. There was no mobility in the implant/tooth, but the patient had some sensitivity to mastication.

TREATMENT APPROACH

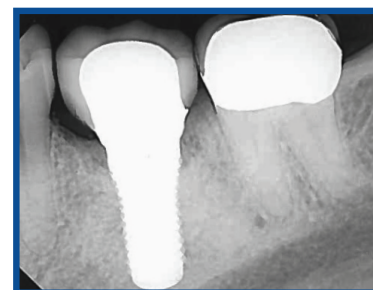LAPIP protocol was performed for the lower left quadrant, which included oral antibiotics and minor occlusal adjustment. The patient was less than compliant and only took half of the antibiotics prescribed. Follow-up care continued for 3-4 months and then the patient resumed seeing her general dentist because her symptoms had subsided.

RESULTS

The patient was referred back to our office two years later per the dentist's request to follow-up on status and prognosis of the implant. Soft tissues were healthy and pocket depths were within normal limits. The only concern was the open embrasure #19/20 are which caught food and caused irritation from time to time. Osseous lesion around mid-section of fixture is no longer present in new x-rays and appears to be normal and stable.



Pre-Op



2 Years Post-Op



ABOUT THE AUTHOR: TODD H. NALLEY, DDS, MS

Dr. Nalley received his dental degree from the University of the Pacific, San Francisco and proceeded onto graduate school at the University of Iowa where he earned a Master of Science degree and Certificate in Periodontics in 1978. In addition, he served as periodontal resident at the VA hospital in Iowa City, Iowa. He trained in the LANAP® protocol for treatment of periodontally involved teeth and implants in 2011. He is a member of the American Academy of Periodontology; the American Dental Association; the California Society of Periodontists and serves as Region Director; and the San Diego County Periodontists and serves as Executive Director. He maintains a private practice limited to Periodontics in Carlsbad, California.

DR. NALLEY
VIDEO TESTIMONIAL

SCAN
QR CODE

